

# Rips, Strips and Broken Tips: Handling the Endodontic Mishap

## PART I: THE SEPARATED INSTRUMENT

Steven J. Cohen D.D.S., Cert. Endo.; Gary D. Glassman, DDS, FRCD(C);  
and Richard Mounce, DDS

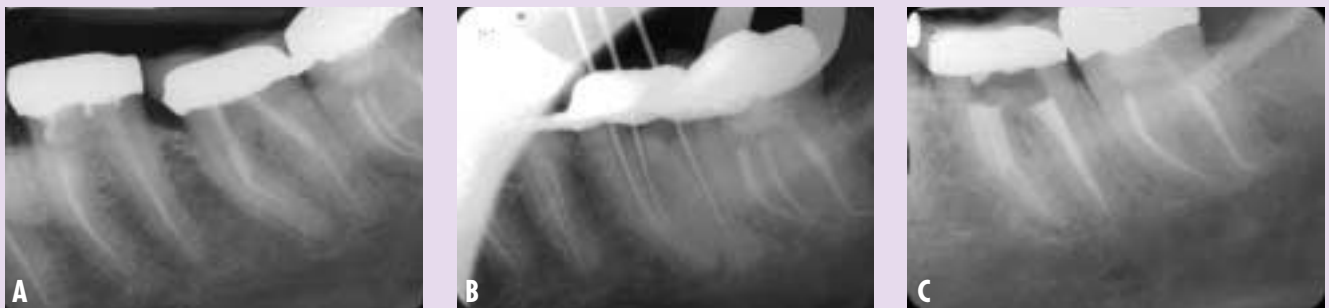### THE MIND SET: "BETWEEN A ROCK AND A HARD PLACE"

The separation of an endodontic instrument instantly transforms a case, from whatever level of difficulty it was pre-operatively, to a new level of severity. Given the variants of anatomy that Mother Nature may have placed in the canals,

roots and/or jaw of that particular patient, we now have added an iatrogenic factor. In the quest to develop better instruments and techniques to improve our quality of care, we have developed a "double-edged sword", an instrument that can cut and shape the dentin wall efficiently, and in the blink of an eye, cut

into the peace of mind of the operator when it separates.

We may have 10 or 12 variations of nickel-titanium files available to drive our way into the canal system, but no sure-fire "antidote" to back out, once separated. Prevention of file separation is always more desirable



**FIGURES 1A, B & C—DANGEROUS CURVES** **A)** Failure to recognize that the mesio-lingual canal has a slight buccal curvature in addition to the obvious distal curve, resulted in file separation in tooth #37. Note the separated files in tooth #38 as well. **B)** Refined access design, and ultrasonics loosened the file for removal. **C)** Obturation of the canal system with sealer and thermoplastic injection of gutta percha.

than attempted removal as is the prevention of any procedural misadventure.<sup>1,2</sup> The consequences of file separation are significant as separation may lead to accompanying uncleaned and unfilled spaces within the root canal system as well as unnecessary removal of excess dentin during removal procedures, which otherwise would not be required had separation not occurred in the first place. This removal of dentin can predispose a clinical case to perforation, root fracture, and difficulty in locating canals even if the file fragment is removed.

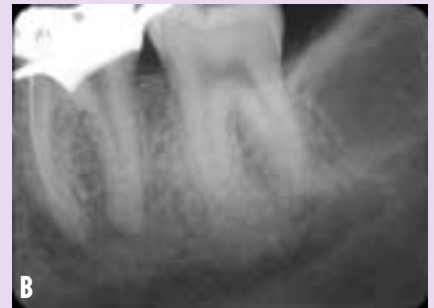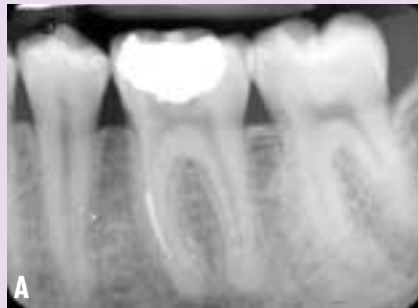There are three possible outcomes that may be encountered when treating these cases: (i) Retrieval, (ii) Bypass and sealing the fragment within the root canal space, (iii) True blockage.

Success of retrieval depends on the canal anatomy, what type of metal the piece is made out of, the location in the canal of the fragment, the plane in which the canal curves, the length of the separated fragment, and the diameter of the canal itself. As an aside, if a file should separate, do not place another rotary nickel titanium file into the canal in an attempt to bypass the first.

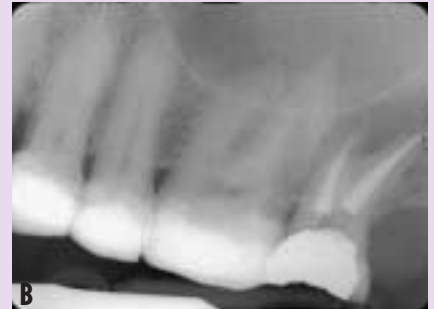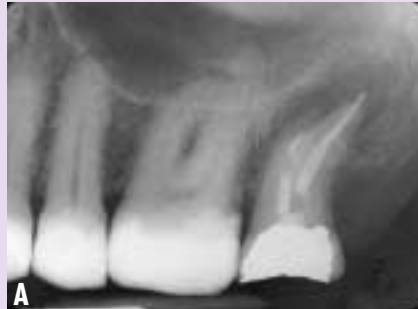The odds of the second file separating are very high and the chances for bypassing the first, correspondingly is very, very poor. Whatever sliver of canal space was available, is now occupied by metal—the “rock”. This is wedged against dentin walls—the “hard place”. The properties that make a nickel-titanium instrument desirable can also be part of its greatest weakness.

Rotation through a curve is great, but rotation through more than one curve in the same canal can be lethal, in terms of the life of the instrument (Figs. 1-4).

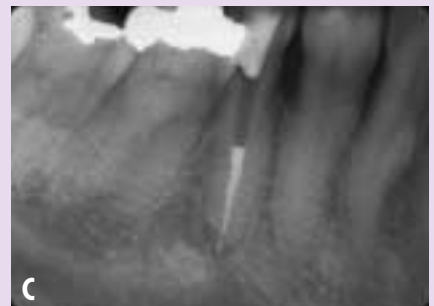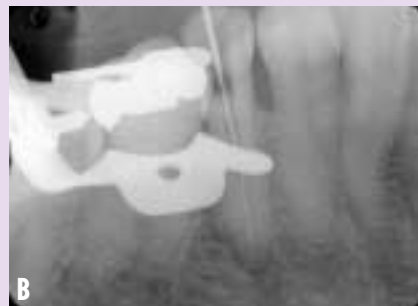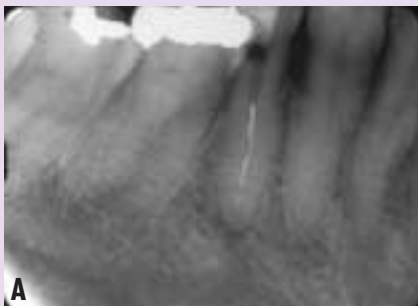Why is it so common to see separated instruments at the middle or apical thirds of the mesial canals of mandibular molars, and at the same location in the mesio-buccal roots of max-



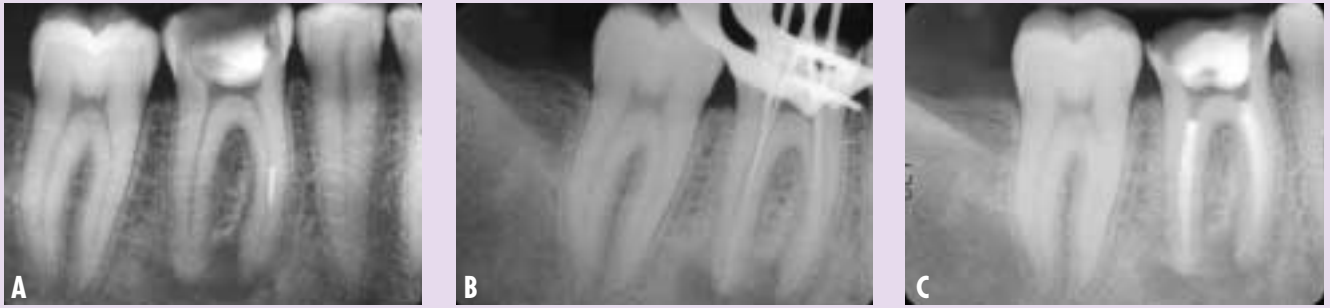**FIGURES 2A & B—DANGEROUS CURVES** **A)** Separated file midroot in tooth #36. **B)** Refined access design, the file segment liberated, and a trial file displaying the double curve in this mesial canal.



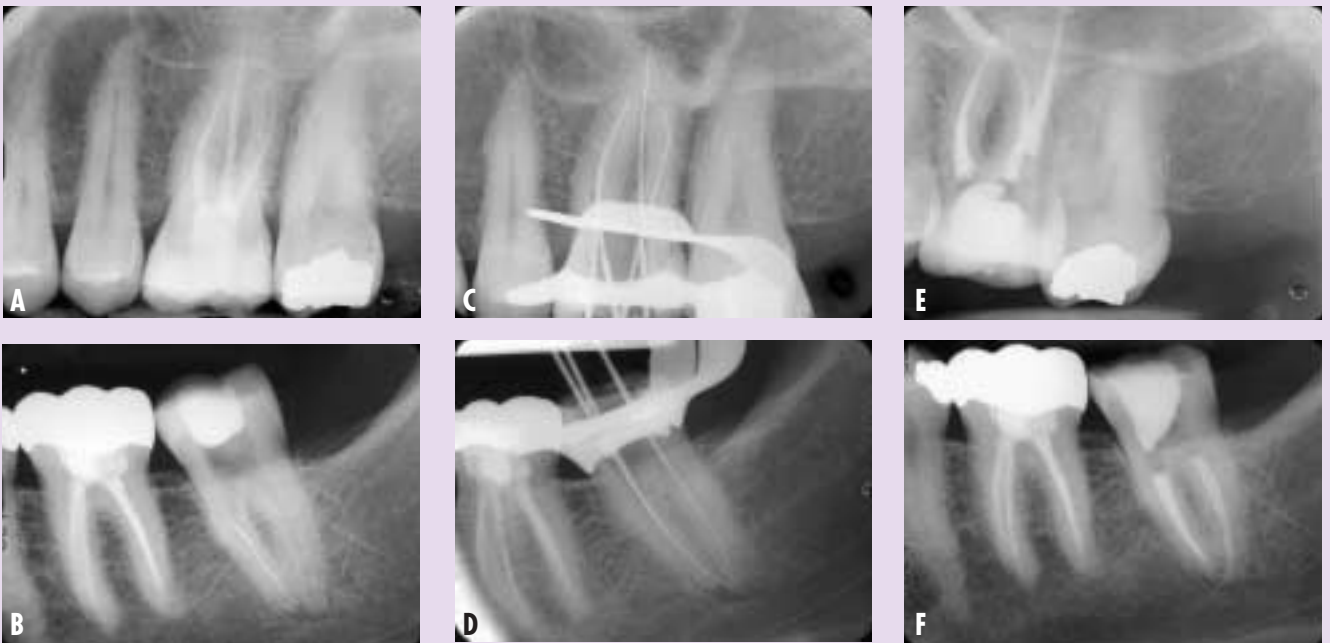
**FIGURES 3A & B—DANGEROUS CURVES** **A)** A two-rooted maxillary 2nd molar, tooth #27, with a separated file noted in the apical third of the buccal root. **B)** Obturation reveals the nature of the “S” curve in the apical third of this root.



**FIGURES 4A, B & C—DANGEROUS CURVES** **A)** Four pieces of broken instrument noted in this mandibular bicuspid, tooth #45. **B)** Removal of three pieces, with the stubborn fourth piece stuck at the the apical third where the canal curves to the lingual. Trial file bypassed the last fragment. **C)** Bypass and sealing the fragment into place, around the apical curve.



**FIGURES 5A, B & C—THE “RUNAWAY GATES-GLIDDEN” BUR** **A)** Improper access design has left a large triangle of dentin narrowing the entrance to the mesial canals. The Gates-Glidden was stressed to the point where the head separated in the middle third of the canal. **B)** Because of the flute design on the bur head, a #10 Hedstrom file could negotiate around the by the blockage. Sequentially larger files, and minimal ultrasonics would loosen and dislodge the file head. Lengths verified by film. **C)** The cleared canal paths are cleaned, shaped and obturated with sealer and thermoplastic injection of gutta percha.



**FIGURES 6A-F—ISOLATION, THOUGHTING AND RETRIEVAL** **A & B)** File located in the mesial root of mandibular molars, or the mesio-buccal root of maxillary molars. **C & D)** Trial file lengths with the segments removed. **E & F)** Completion of endodontic therapy.

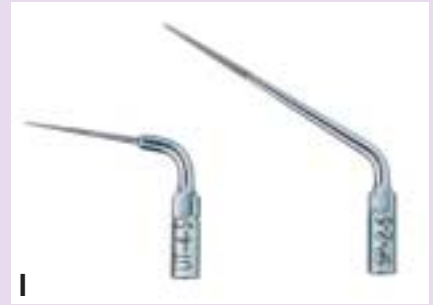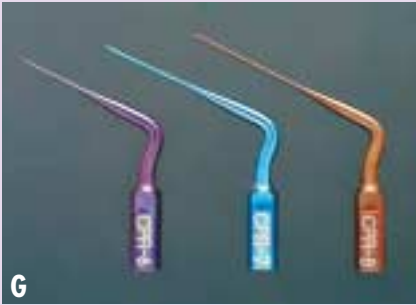illary molars? It is because of root canal curvatures! These roots not only characteristically curve distally (in the two dimensional view, on a periapical film), but often the MB canal curves lingually, and the ML canal curves slightly to the buccal. These lingual and buccal curves are not visible on the film.

The first clue to treatment is to look at the location of the file seg-

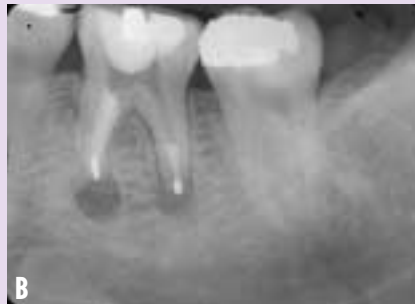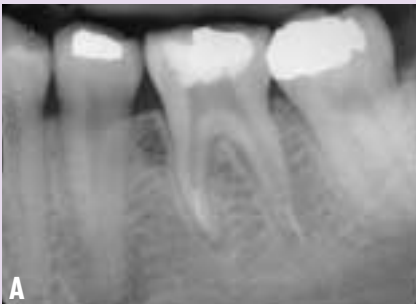ment—and at that point, some force acted to cause fracture of the instrument. If the canal appears straight, assume there is a curve in the plane of the radiographic beam. If there is a visible curve in the canal, assume there is a second curve that is not visible. This of course does not account for manufacturers’ error. Anecdotal reports are many, where the clinician states that the file was taken from a brand new package and

put into its first use where it immediately separated.

Although it is possible to have manufacturing defects, we believe that file separation usually occurs with how the file is used. If a glide path is created with stainless steel instruments prior to a crown down sequence of rotary NiTi file use, engagement of the file on the root canal wall will be minimized thereby reducing



**FIGURES 6G-K—ISOLATION, TOUGHTING AND RETRIEVAL** **G)** CPR™ titanium tips (Spartan/Obtura, Fenton, MO). **H)** CPR™ diamond coated tips (Spartan/Obtura, Fenton, MO). **I)** UT-4-S™ and the SP-2-S™ (SybronEndo, Orange, CA). **J)** Mini Endo Ultrasonic Unit (SybronEndo, Orange, CA). **K)** Spartan-MTS Unit (Fenton, MO).



**FIGURES 7A & B—SURGICAL RETRIEVAL** **A)** Two separated files, apical to the curve in the mesial root, and part way through the apical constriction in the distal root. **B)** The canals were treated conventionally first, then apical surgery was performed at the same appointment to remove these fragments and seal the apices.

this point, some special attention should be paid to the access design. Attempted removal without an operating microscope is a low yield operation. Conversely, using an operating microscope greatly increases the chances for retrieval. Attempting to remove a fragment without adequate visualization highly risks perforation as root curvatures, even though not radiographically visible can easily mislead the clinician to remove dentin where it will have little benefit toward file removal.<sup>3</sup>

stress and fatigue and therefore preventing fracture.

Some devices and/or systems are available, designed for fragment retrieval, based on a “tube-sleeve-fit” principle. The separated fragment is identified, and the coronal end is liberated from surrounding dentin via ultrasonic tips. The “tube” is placed over the end, and a locking mechanism or an adhesive is applied. The fragment is then withdrawn. Although some systems are workable, the main disadvantage of this technique is that

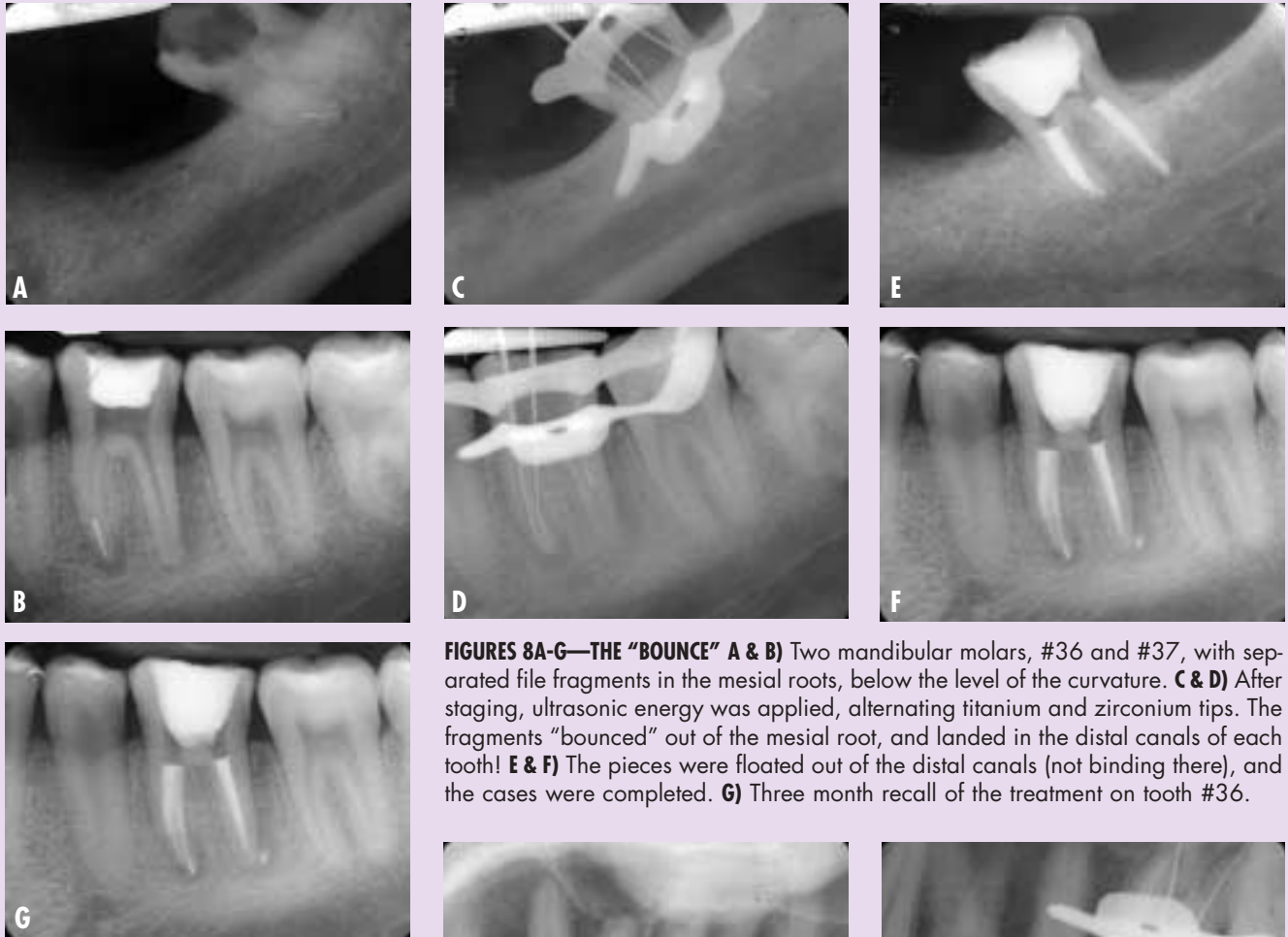
a large, dense root is required to work in, as the diameter of the tubes can be quite large. Getting into the apical third of a smaller, curved root may be next to impossible for this type of device. For these cases, getting between the “rock and the hard place”, and loosening the “rock” with minimal distortion to the hard dentin walls is a better strategy.

**TECHNIQUE**

**Step 1: Optics and Staging**

Under the operating microscope, access is made into the tooth. At

The “runaway Gates-Glidden” is an example of the instrument being asked to do more than its design could handle (Fig. 5). There was an overhanging dentinal ledge at the chamber roof level, another triangle of dentin at the mesial canal orifice, and no true glide path was established. Although rare, this Gates-Glidden bur separated at the head, and not at the shaft as per usual. This is a factor of the stress put on that instrument in that canal. A rush to use rotary instruments without establish-



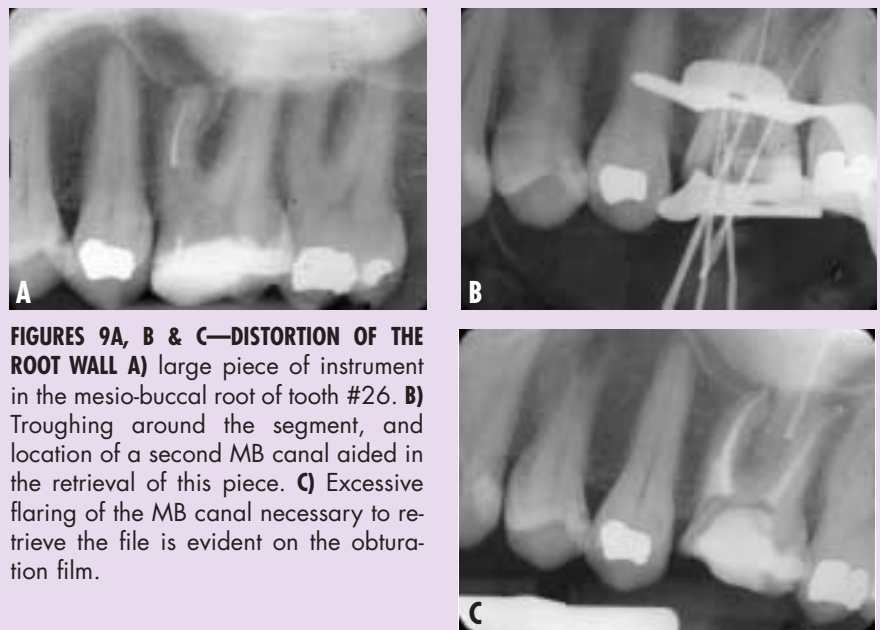
**FIGURES 8A-G—THE “BOUNCE”** A & B) Two mandibular molars, #36 and #37, with separated file fragments in the mesial roots, below the level of the curvature. C & D) After staging, ultrasonic energy was applied, alternating titanium and zirconium tips. The fragments “bounced” out of the mesial root, and landed in the distal canals of each tooth! E & F) The pieces were floated out of the distal canals (not binding there), and the cases were completed. G) Three month recall of the treatment on tooth #36.

ing a proper straight-line access and a true glide path is a major contributing factor to separation.

Access is redefined, from the occlusal surface to the level of the pulp horns, to the orifice, straight down as far as practical into the canal space. This canal space coronal to the fragment can then be “staged”, where blunted Gates Glidden burs are used in a crown-down fashion to open the canal space to the limit of the broken instrument. At this point, visualization of the coronal end of the fragment should be possible under medium to high power on the microscope.

**Step 2: Troughing (Fig. 6)**

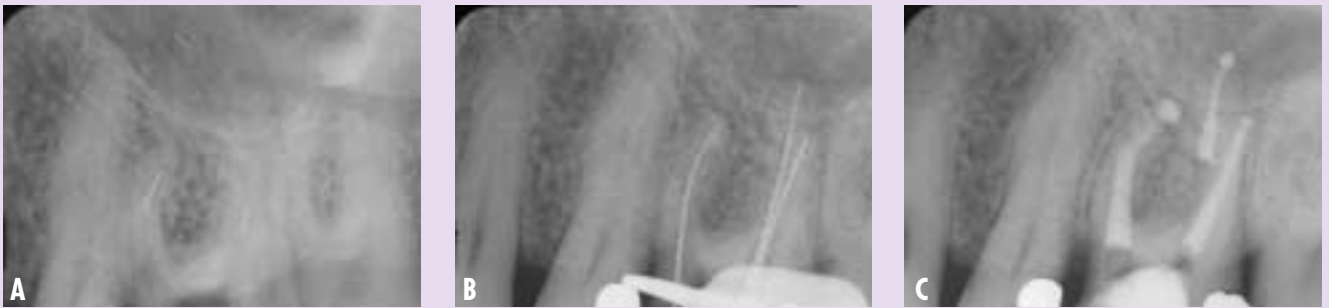A selection of ultrasonic tips is



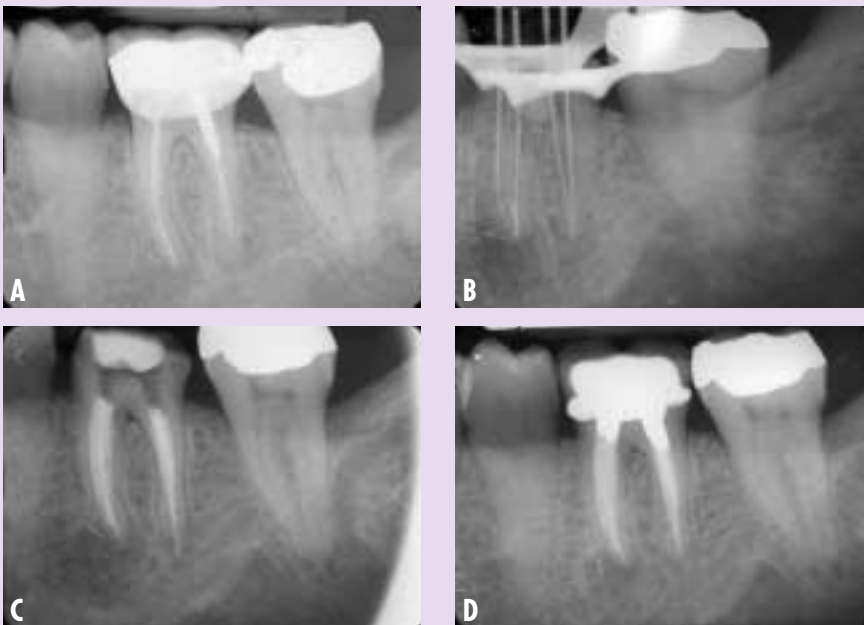**FIGURES 9A, B & C—DISTORTION OF THE ROOT WALL** A) large piece of instrument in the mesio-buccal root of tooth #26. B) Troughing around the segment, and location of a second MB canal aided in the retrieval of this piece. C) Excessive flaring of the MB canal necessary to retrieve the file is evident on the obturation film.

available to use at this stage. A long, thin CPR™ #8 titanium tip (Spartan/Obtura, Fenton, Missouri) (Fig. 6G) can be used at lowest power, with the tip applied to circumferentially remove dentin around the free end of the in-

strument. This is a slow, careful removal of dentin, with intermittent water and air coolant used. This is continued until some length of the file is standing free within the canal space, and some movement of the fragment is



**FIGURES 10A, B & C—BYPASS AND SEALING INTO PLACE** **A)** Small fragment located in the apical third of the MB root of tooth #26; small fragment also noted in the midroot level of the DB root. **B)** Removal of the DB fragment. Reduction of the size of the piece in the MB canal, and bypassing to the apex. **C)** Obturation incorporating the remaining segment into the fill.



**FIGURES 11A-D—BLOCKAGE, SEALING AND FOLLOW-UP** **A)** Tooth #36, referred for retreatment, with a fragment noted at the apex of the mesial root. A small piece of instrument also noted beyond the apex, with the lesion of the mesial root. **B)** Trial file film, showing the true blockage in the ML canal. **C)** Post Obturation film. **D)** One-year recall, lesion reduced in size, asymptomatic, tooth restored.

noted. Once some movement is seen, a second diamond coated zirconium tip, such as the CPR™ (Fig. 5D) (Spartan/ Obtura, Fenton, Missouri) (Fig. 6H), the UT-4-S™ or the SP-2-S™ (SybronEndo, Orange, CA) (Fig. 6I), can be applied with the tip activated once in contact with the metal fragment only.

The diamond coating makes this a very aggressive cutting tip if it comes into contact with the

dentin walls. The application of two different types of metal tips at two different frequencies can produce a jarring effect that can “bounce” the metal fragment coronally within the canal. Care should be taken here, to only remove dentin along the outer safe wall of the canal.

Twin ultrasonic units such as the Mini Endo Unit (SybronEndo, Orange, CA) (Fig 6J) or the Spartan-MTS Unit (Fenton, Missouri)

(Fig. 6K) can be most efficient for this, where the two different tips are loaded and ready to go. Also, one unit can be programmed to run with water, while the adjacent ultrasonic handpiece can run dry. The intermittent water and air coolant (Stropko™ (Sybron-Endo, Orange, CA) device on the air/water syringe), and two different metal surfaces activated on the fragment, in many cases, can loosen and even dislodge the metal piece. Unfortunately, this process is very tedious and can often take one whole working appointment (60 to 90 minutes). The ultrasonic tips often wear out or break during this procedure. In a difficult case, this should be an expected event.

The difference in metals (the fragment) is most notable during this stage. A stainless steel fragment absorbs the ultrasonic energy bodily, and will show movement early on. It also distorts easily. A nickel-titanium fragment absorbs the energy at and/or near the point of contact with the tip, and can result in the fragment gradually getting smaller, as the flutes are worn away by the energy applied. The property of “memory”, where the NiTi file tends to return to its straight shape when removed from the canal, is a major drawback in trying to remove this

fragment. When dentin is removed to free up a binding point, the file straightens even further and binds again. Sometimes, the NiTi fragment is seen to reduced flute by flute as the process continues, and may result in a non-retrievable smaller piece lodged in the canal below the level of the curve. These cases have the poorest prognosis (true blockage) and that fragment may only end up being liberated by surgery (Fig. 7).

It is important as much as possible to not touch the fragment but rather to remove dentin selectively around the fragment such that the file resists breakage that usually results from touching the nickel titanium metal directly. In addition, ultrasonic energy is relayed upon the file fragment through the thin dentin surrounding the file increasing the possibility that the entire fragment will be removed in total.

**Step 3: Bypass, Loosen, Bounce**

With the fragment showing movement when ultrasonic energy is applied, a small (.06 or .08) carbon steel hand file (SybronEndo, Orange, CA) can be utilized to try and bypass the loose piece. The carbon steel is end-cutting, and a harder metal that either stainless or nickel-titanium. Once bypassed, you have now regained the canal space lost on the initial separation of the instrument. This should be repeated with gradually increasing diameter sizes of files. As the canal space opens around the fragment, ultrasonic energy again (diamond coated tip) will help to jar the fragment and can cause a “bounce” where it will move coronally within the canal space (Fig. 8).

With enough movement, the file should be able to be retrieved. It is important to realize that

once bypassed, maintaining the patency achieved is the key to success. It would be easy to simply push the loosened fragment back down into the canal if too much force was used and or increasingly larger K files were advanced too quickly in succession. In practical terms, it may be necessary to use a large number of #6-#10 K files (SybronEndo, Orange, CA) to achieve patency and create a space alongside the fragment such that the path of the canal can be reproducibly entered and enlarged.

As mentioned earlier, it is ill advised to place another rotary

*If the bulk of the canal space has been soaking in full strength sodium hypochlorite, and the critical concentration of bacterial contaminants within the canal are sufficiently reduced, the body may heal around this root as well.*

nickel titanium file alongside the first separated fragment especially if the fragment has not been removed. It may have clinical value to gently use a Hedstrom file to try and engage the file fragment and tease it upward using a straight up and down vertical motion. The Hedstrom can often engage the fragment and produce its release when a K file cannot. If the file fragment cannot be removed either with ultrasonics or removal via the Hedstrom as mentioned (and the canal is negotiable with hand files), it has value to shape the canal space beyond the fragment by hand and not intro-

duce a rotary nickel titanium file.

Even though the path of the canal is negotiable, the likelihood of another separation in this clinical situation is very high.

**LIMITATIONS**

A severe curve in the root will limit the amount of dentin that can be removed along the “safe” wall (Fig. 9). Perforation through the side of the root is not uncommon, and knowledge of root anatomy and experience dictate when the clinician must stop before pushing the ultrasonic dentin removal too far. Not all cases will end in retrieval.

Bypass and sealing the fragment into place can be very successful, if the canal is thoroughly cleaned around the obstacle, and the apical terminus is sealed (Figs. 10 & 11). True blockage also does not mean automatic failure. If the bulk of the canal space has been soaking in full strength sodium hypochlorite, and the critical concentration of bacterial contaminants within the canal are sufficiently reduced, the body may heal around this root as well.

The above notwithstanding, the vast majority of separated instruments can be removed if done so with care, time and the right experience and armamentarium, irrespective of which third of the canal the separation has occurred. **OH**

*Bios...*

**REFERENCES**

1. Grossman LJ. Guidelines for the prevention of fracture of root canal instruments. *Oral Surg Oral Med Oral Pathol.* 1969 Nov;28(5):746-52.
2. Tidmarsh BG. Preparation of the root canal. *Int Endod J.* 1982 Apr;15(2):53-61.
3. Wong R, Cho F. Microscopic management of procedural errors. *Dent Clin North Am.* 1997 Jul;41(3):455-79.

@ARTICLECATEGORY:594;